


www.aiyssssa.org
All India Youth Sikh Sangat Sewa Samiti
Association (NGO)

www.aiyssssa.org
RUN E

E
w
RUN
NGO

AIYS
[www.a](http://www.aiyssssa.org)
All India Youth
Asso

Ekor
www.ekor
IN BY: AIYS



0:01 | 0:27

सेवा मे

Ravinder Singh Bhatia Ji
All India Youth Sikh Sangat Sewa Samiti Association.

मोहकथ जी

प्रिय

विद्वान राज मेहता

मेरी बच्चा का नाम

है मेरी बच्चा का आई केंद्र है।

आई मेरी बच्चा का ईमान मामुस मे
चल रह है। मेरी आप से निवेदन है।

कि आप लोग मेरी बच्चा का ईमान
मे भद्र कर मे बारखंड मे मजदुरी

करवा है आई मे आपना बच्चा
का ईमान नहीं करा पा रहा है।
निवेदन है। मेरी बच्चा का ईमान
मे मेरी आप लोग भद्र कर

पिता का नाम विनेश मेहता
विनेश मेहता

माता का नाम
संजु देवी

संजु देवी



भारत सरकार
GOVERNMENT OF INDIA



दिनेश कुमार मेहता
Dinesh Kumar Mehta

जन्म वर्ष / Year of Birth : 1993
पुरुष / Male



9199 0129 6842

आधार — आम आदमी का अधिकार



भारतीय विशिष्ट पहचान प्राधिकरण
UNIQUE IDENTIFICATION AUTHORITY OF INDIA

पता: S/O ब्याश मेहता, ग्राम-पोखराहा
खुर्द थाना-मेदिनीनगर, डालटनगंज,
रजवाडीह, पलामू, झारखण्ड, 822118


Address: S/O Byash Mehta,
VILL-POKHRAHA KHURD
PS-MEDININAGAR,
DALTONGANJ, Rajwadih,
Palamu, Jharkhand, 822118



1947
1800 180 1947



help@uidai.gov.in



www.uidai.gov.in

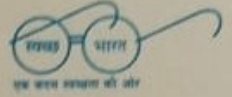

P.O. Box No. 1947,
Bengaluru-560 001



अ० भा० आ० सं० अस्पताल / A.I.I.M.S. HOSPITAL
बहिरंग रोगी विभाग / Out Patient Department

अस्पताल के अन्दर धूम्रपान मना है। / SMOKING IS PROHIBITED IN HOSPITAL PREMISES



शरीरमाद्य खलु वर्ज्यसाधनम्

एकक/Unit

विभाग/Dept.

नाम/Name

रोगी विवरण विभाग

UHID: 106532389

Dept No: 20230030005211

रूम/Room

OPR-6

D. Regn. No.

पता/Address

प्रितम राजपुत प्रितम राजपुत
PRITAM RAJPUT

31 MSD / MSc

SONWESH MENTA

Add: POHRANA DALTEN

PAWCHARANA, JHARKHAND, INDIA

Mob: 7488864879

New Patient

General

ID

Reporting: 1:30 PM

14

PCSC PAEDS

Queue No: N10

23/02/2023



निदान/Diagnosis

(R) EORB

दिनांक/Date

उपचार/Treatment

28

outside CD - corrupt
→ could not be discussed
in RC today

Dr Satyendra
R NO. 34

Plan: - To discuss MRI
films E R D
faculty tomorrow
- FU on 25/2/23
(Saturday) 9 AM
S

Rv in Red one OPD on 1/3/23

Room (14)

04/02/23

To review in Medical oncology OPD on
06/01/2023

Kashu
SR oncology



Pradhan Mantri Jan Arogya Yojana
Ayushman Bharat
PM-JAY
आरोग्य काल आरोग्य योजना
(pmjay.gov.in)

CLEAN AND GREEN AIIMS / एम्स का यही संकल्प, स्वच्छता से काया कल्प

अंगदान-जीवन का बहुमूल्य उपहार / ORGAN DONATION - A GIFT OF LIFE

O.R.B.O., AIIMS, 26588360, 26593444, www.orbo.org Helpline - 1060 (24 hrs service)



मेरा अस्पताल
My Hospital
meraaspatal.nhp.gov.in

Unisuperative

ब० रो० वि० कार्ड
O.P.D. Card

दृष्टि



नैत्र अग्रणी उपचार है जो आप ही दे सकते हैं

अनुभाग व दिन
Section and Day VI
बुधवार व शनिवार
Wednesday & Saturday

कमरा नंबर
Cabin No.

डा० र
अ० र
Dr. F
A.I.
यू० ए
UH

R. P. Centre (Eye Centre)

UHID: 106532389
Dept. No. 20230050020897
PRITAM RAJPUT
S/O: DINESH MEHTA
3Y/M

Date: 18/02/2023
General
RPC OPD-Dr. SR/JR
UNDER UNIT-VI R.34B
Unit-VI
WED, SAT
Room No.: 34B

Address: POKHRAHA DAALTEN PANPOKARANA, JHARKHAND, INDIA
Mobile: 7488884879

Barcode

248

दिनांक DATE	निदान DIAGNOSIS	उपचार Treatment
<p>VA < does not follow light</p> <p>W < dig (N)</p> <p>No other SI</p>	<p>(R) eye EORB (Det at 4 months of age)</p> <p>#3 cycle of VEE. chemo to upto 1AC</p> <p>clo to 1AC</p> <p>Q/E OPD - Proptosis & exposure keratitis.</p> <p>of (Tordilign) - conj (N) lens clear AC formed.</p>	<p>Daughter MIA history not reliable informant: father</p>

कृपया इस कार्ड को सुरक्षित रखें तथा अस्पताल में दिखाने के समय हर वक्त साथ लायें।

Kindly keep this Card safely and bring it on your follow-up visits.

- धूम्रपान निषेध 1. No Smoking
- कूड़ा कर्कट केवल कूड़ेदान में ही डालें 2. Use Dustbin
- थूकिये नहीं 3. No Spitting



प्रयोगशाला अबुर्द विज्ञान, डॉ भीमराव अम्बेडकर संस्थान रोटरी कैंसर अस्पताल
अखिल भारतीय आयुर्विज्ञान संस्थान नयी दिल्ली -110029
LABORATORY ONCOLOGY, Dr B.R.A. Institute Rotary Cancer Hospital All India Institute
of Medical Sciences, New Delhi-110029

UHID:	105270382	Reg Date :	12/11/2020 11:23 AM
Patient Name :	Mr PRITAM RAJ MEHTA	Age :	2 years 9 months 15 days
Sex :	Male	Unit Name :	Unit-I
Department :	Medical Oncology	Sample Collection Date:	10/03/2023 12:21 PM
Unit Incharge :		Lab Sub Centre:	Lab Oncology (IRCH)
Lab Name:	Oncology Lab	Report Generated Date:	11/03/2023 03:17 PM
Sample Received Date:	10/03/2023 02:40 PM	Recommended By:	Dr. Animesh Gupta IRCH
Dept / IRCH No:	248624		
Lab Reference No:	377		

Sample Details : LOI-100323129-CS (CSF)**CSF For Morphology**

C-377/23.

CSF cytospin smear is acellular.

Senior Resident: Dr Gaddam Pranitha

Consultant Dr Sanjeev K Gupta

REMARKS:-

This is an electronically generated report, authorized signature is not required. The test reports have been authenticated.
Partial reproduction of the report is not permitted.

Authorized Signatory



LABORATORY ONCOLOGY UNIT, Dr B.R.A. IRCH, AIIMS, New Delhi & NCI-JHAJJAR, AIIMS

Requisition form for Routine Investigations

UHID :

Name :

Age/Sex :

• Clinical Diagnosis:

• Clinical Details:


• Payment status:

Paying

EHS (No :)

Exempted by (Sign and Stamp)

Investigation Requested

Parameters	Cost	Parameters	Cost	Parameters	Cost	Parameters	Cost
CBC+DLC	Free	Total Bilirubin	Free	FSH	200	HIV	Free
CBC+DLC+ Reticulocyte	Free	Direct Bilirubin	Free	LH	200	HBsAg	Free
PT	Free	SGPT/ALT	Free	Estradiol	225	HCV	Free
INR	Free	SGOT/AST	Free	Progesterone	225	IgG	Free
APTT	Free	Total protein	Free	Cortisol	200	IgA	Free
TT	Free	Albumin	Free	Vitamin D	200	IgM	Free
D Dimer	Free	Alkaline Phosphatase	Free	Testosterone	200	AFP	Free
Fibrinogen	Free	GGT	Free	TSH	200	CA125	500
Glucose R	Free	Amylase	Free	FT3	Free	CA19.9	100
Glucose F	Free	Lipase	Free	FT4	Free	CEA	225
Glucose PP	Free	Magnesium	Free	T3	200	PSA	275
GTT-50g Glucose	Free	Cholesterol	125	T4	200	Free PSA	Free
GTT-75g Glucose	Free	Triglyceride		Vitamin B12	100	β-HCG	Free
GTT-100g Glucose	Free	VLDL		Folate	Free	HbA1c	150
Urea	Free	LDL		Homocysteine	Free	Requesting Doctor Name Sign  Seal	
Creatinine	Free	HDL	25	Iron	Free		
Uric Acid	Free	LDH		Transferrin	100		
Calcium	Free	CRP		Ferritin	Free		
Phosphorus	Free	IL-6	Free	TIBC	Free		
Sodium	Free	Procalcitonin	1350	Troponin	35		
Potassium	Free	Prolactin	200	CK-NAC	125		
Chloride	Free	PTH	200	CK MB	100		

Remarks:

PATIENT'S NAME: PRITAM RAJ MEHTA	AGE/SEX: 3/M
REF. BY: DR. AIIMS	REG. ID: PRA2779
TEST NAME: 3T MRI SCAN - MRI HEAD & ORBITS	EXAM. DATE: 18-FEB-2023

CEMRI-HEAD AND ORBITS

TECHNIQUE: -

MR IMAGING OF THE BRAIN WAS PERFORMED, MR SCANNER USING HEAD COIL. T1 FLAIR, FSE T2, GRE T2*-- AXIAL, FSE T2-- SAGITTAL AND T2 FLAIR CORONAL IMAGES WERE ACQUIRED. THE STUDY WAS SUPPLEMENTED WITH DIFFUSION WEIGHTED IMAGES USING EPI SEQUENCE. POST CONTRAST IMAGES IN AXIAL, CORONAL AND SAGITTAL PLANES.

CLINICAL DETAILS: - H/O RETINOBLASTOMA FROM 2 YEAR BACK. 2 CHEMO CYCLE DONE, C/O SWELLING IN RIGHT EYE FROM 15 DAYS.

OBSERVATION: -

The study reveals no significant focal lesion in the brain. The cerebral parenchyma shows normal signal characteristics. Myelination pattern of the brain is normal.

No evidence of restricted diffusion noted.

The basal ganglia, thalami and internal capsules appear normal.

The mid-brain, pons and medulla appear normal. The cerebellum appears normal.

The ventricular system appears normal. The septum is in mid line. The sulci, fissures & basal cisterns appear normal.

The pituitary gland, optic chiasm and bilateral parasellar regions appear normal.

The corpus callosum appears normal.

Intracranial vascular structures in view are normal.

No abnormal parenchymal or leptomeningeal enhancement is noted in brain parenchyma.

Bilateral seventh-eighth cranial nerve complexes and inner ear structures are normal. Both CP angle cisterns are normal.

There is a large lobulated heterogeneous mass lesion in retro-orbital region, posterior and superolateral to the ocular globe involving the ocular globe extending to the ocular globe completely occupying the right ocular globe with involvement of the anterior and posterior compartment, iris lens complex and extending retro-orbital region, right lateral superior and posterior retrobulbar region, completely occupying the retrobulbar

Disclaimer: It is an interpretation of medical imaging/diagnostic based on clinical data. All modern machines/procedures have their own limitation. This is neither complete nor accurate; hence, findings should always be interpreted in the light of clinico-pathological correlation. This is a professional opinion, not a diagnosis. Not meant for medico legal purposes. Any typographical error should be informed and report sent for correction within 7 days.



011 - 40727900
+91 9599464433



info@sakshamimaging.com
http://sakshamimaging.com

A-1/10 GROUND FLOOR & BASEMENT,
SAFDARJUNG ENCLAVE, NEW DELHI - 110029